

# Use of Whole Slide Imaging in Surgical Pathology Quality Assurance: Design and Pilot Validation Studies

Jonhan Ho, MD, Anil Parwani, MD, PhD, Drazen Jukic, MD, PhD, Yukako Yagi, Leslie Anthony, MA, John Gilbertson, MD  
University of Pittsburgh, School of Medicine, Department of Pathology

## Objective

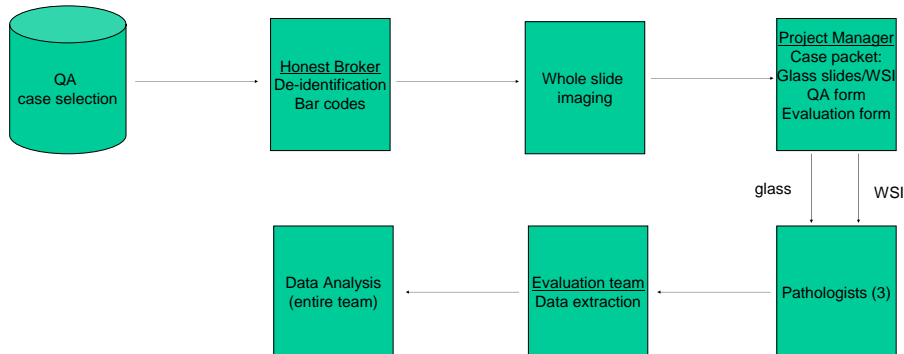
To analyze the applicability of whole slide imaging in the current surgical pathology quality assurance workflow.

## Methods

This was a retrospective, comparative study in which 24 full genitourinary pathology cases were selected randomly by the quality assurance division using standard quality assurance protocols. Cases were de-identified and slides imaged to 0.46 um/pixel using an Aperio T2 commercial whole slide imager (Aperio Technologies, Vista CA). For each case, study pathologists were randomized to either a traditional glass slide review approach or a review based on digital slides so that each case got two independent reviews, one with glass slides and one with digital slides. At the end of the study, diagnostic discrepancies were evaluated by a pathology consensus committee. Glass slide diagnoses were compared with whole slide image diagnoses.

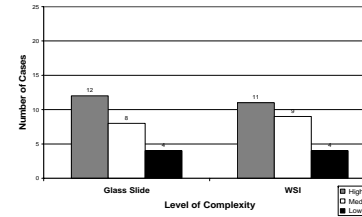
The 24 cases represented 47 surgical parts and 391 individual slides. There were nine prostate biopsies (representing 29 parts) and five bladder biopsies (representing 6 parts). Other cases included transurethral resections, prostatectomies, nephrectomies, two vasectomies and a scrotal lesion. The slides included 29 special stains, two frozen sections and two touch preps. Approximately half the cases had a diagnosis of cancer or in situ neoplasia in the line diagnosis.

Case Type	Number of Cases	Number of Parts	Number of Slides
Prostate Biopsy	9	29	214
Bladder Biopsy	5	6	21
TURP	3	3	23
Radical Prostatectomy	2	4	98
Nephrectomy	2	2	24
Vasectomy	2	2	9
Excision of a scrotal lesion	1	1	2
Total	24	47	391

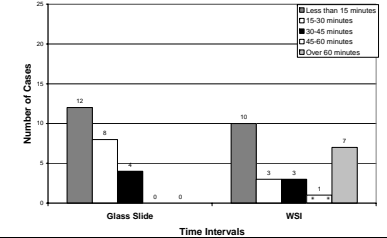


## Results

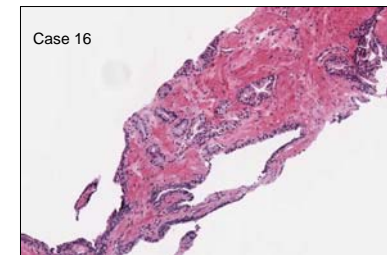
Case Complexity



Time to Complete



Case Number	Case Type	Disagreement	Consensus
Case 10	Prostate Needle Biopsy	WSI Review: Gleason 3+4=7 Signed Out Report: Gleason 3+3=6	Agreement with the signed out report
Case 16	Prostate Needle Biopsy	Glass Review: Foci of carcinoma Signed Out Report: No foci of cancer in the core in question	Moderate, clinically insignificant disagreement with signed out report
Case 19	Radical Prostatectomy	WSI Review: High grade PIN Signed Out Report: No mention of high grade PIN	Mild, clinically insignificant disagreement with the signed our report
Case 21	Prostate Needle Biopsy	Glass Review: No evidence of atypia Signed Out Report: Foci of atypia	Agreement with the signed out report
Case 29	TURP	WSI Review: Spelling error in report	Spelling error present but not clinically significant



## Conclusions/Future Directions

Automated whole slide imaging is a potential modality for surgical pathology quality assurance. Digital slides have advantages over physical slides especially in multi-facility health systems that would like to establish inter-facility quality assurance without having to manage the logistics of moving large numbers of slides between institutions. Significantly, the participants also felt that major issues limiting the implementation of WSI based quality assurance did not involve image quality or the imaging robot but rather image management and integration issues such as the pathologist's user interface, the hospital's network and image integration with the laboratory information system.